

A case revealing the natural history of untreated Lyme disease

Robert T. Schoen

Background. A 71-year-old woman presented to a rheumatologist with what she believed to be a 2-year history of Lyme disease, progressing from erythema migrans to Lyme arthritis.

Investigations. History, physical examination and serologic testing confirmed the diagnosis of Lyme disease.

Diagnosis. Lyme disease.

Management. The patient refused antibiotic therapy during the first 2 years of her illness. During the next 2 years, she consulted a rheumatologist, but declined antibiotic therapy. She continued to have recurrent episodes of arthritis, following which she was successfully treated with doxycycline, given initially for 2 weeks, with a second, 4-week cycle administered 2 months later. This case illustrates the natural history of untreated Lyme disease, which is rarely observed in most patients since diagnosis almost always leads to successful antibiotic treatment. Furthermore, this case also demonstrates that infection with *Borrelia burgdorferi* can persist for years in untreated patients; however, antibiotic therapy is still likely to be effective, despite long-term infection.

Schoen, R. T. *Nat. Rev. Rheumatol.* 7, 179–184 (2011); published online 21 December 2010; doi:10.1038/nrrheum.2010.209

The case

A 71-year-old woman from Northeast USA presented to a rheumatologist with a 4-month history of swelling of her left knee (See Figure 1 for timeline). Two years before presentation, the patient noted what she described as a “deer tick” bite on her right arm. She subsequently developed an expanding erythematous rash at the bite site without any other symptoms. She suspected early-stage Lyme disease and consulted her homeopath, who treated her with homeopathic remedies, but not with antibiotics. The rash resolved after about 2 weeks, but 2 months later she developed a mild headache and stiff neck.

The following year, she had a brief episode of left ankle pain and swelling, followed 6 months later by right elbow pain and 3 weeks of right shoulder pain. The patient consulted the homeopathic doctor again and was prescribed further homeopathic treatments.

Five months before presentation to the rheumatologist, she developed pain in the left knee on flexion, followed by marked swelling of the left knee over the next 2 months. The patient returned to the homeopath, who tested her for Lyme disease (enzyme-linked immunosorbent assay [ELISA] = 8.95 [normal range is <0.9]; Western blot: negative for IgM, positive for IgG). The homeopath diagnosed Lyme arthritis and recommended a course of doxycycline for 28 days, but the patient declined the antibiotic.

She made an appointment to see a rheumatologist (Figure 1; first presentation), but while waiting for the visit, she consulted an acupuncturist for treatment. During this period, the swelling in her left knee improved. When seen by the rheumatologist, she appeared well, except for a mildly tender left-knee effusion. The rheumatologist confirmed the diagnosis of Lyme arthritis and prescribed amoxicillin (500 mg, three times daily for 28 days) to hasten the resolution of the current episode of arthritis and to prevent subsequent flare-ups. The patient initially agreed to take this treatment and to return at the completion of antibiotic therapy. When seen a month later, however, she had not taken any of the prescribed antibiotic therapy. Nevertheless, the arthritis of the left knee had resolved and she had no other joint abnormalities.

The patient had no further arthritis until approximately 2 years after the initial presentation to the rheumatologist, when she developed left-knee swelling that persisted for 2 days, and recurred for another 2-day episode after a 4-month interval. She again sought acupuncture therapy after the second episode of left-knee swelling, which initially improved, but then returned and persisted for a month. Subsequently, the left-knee swelling became worse and she also developed a pain in the right knee. She returned to the homeopath, who recommended a course of doxycycline therapy (100 mg, twice daily for 14 days), which she agreed to adhere to. No immediate improvement was observed in her arthritis, however, so she decided on her own to discontinue the antibiotic

Section of
Rheumatology, Yale
University School of
Medicine, Suite 6A,
60 Temple Street, New
Haven, CT 06510, USA.
robert.schoen@
yale.edu

Competing interests

The author declares no competing interests.

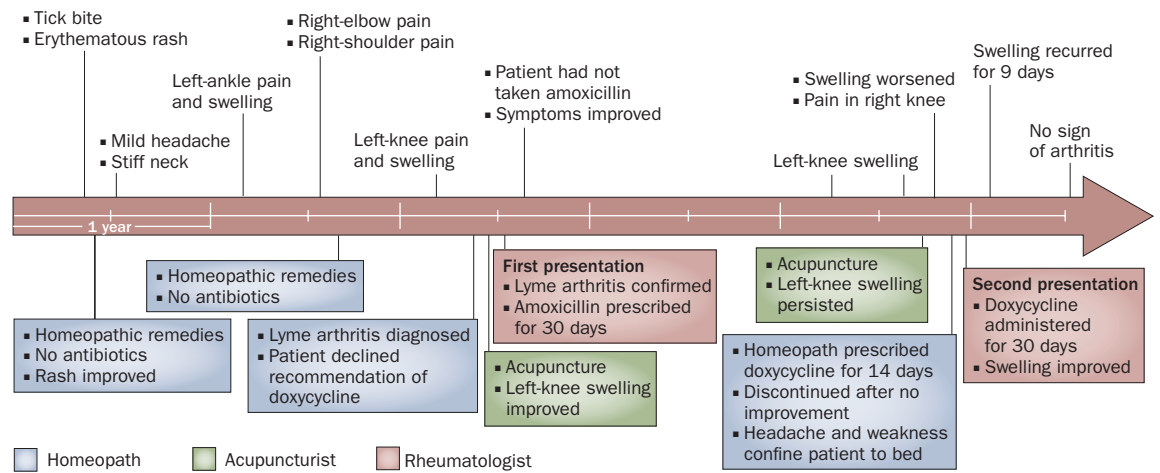


Figure 1 | Timeline of the case illustrating the natural history of Lyme disease. Visits to the homeopath, acupuncturist and rheumatologist are color-coded and displayed below the timeline.

therapy. She confined herself to bed for 24 days because of the knee pain, weakness and a headache. One month later, she had some decrease in the left-knee swelling and resolution of the headache and weakness.

Following her self-confinement, the patient returned to the rheumatologist (Figure 1; second presentation). He reviewed the testing done 1 month previously by the acupuncturist, including the repeat Lyme-disease testing, for which she was positive (ELISA >5.00; Western Blot, negative for IgM, positive for IgG), and the erythrocyte sedimentation rate (121 mm/h). Physical examination by the rheumatologist revealed a 1+ effusion of her left knee.

The rheumatologist prescribed doxycycline therapy (100 mg, twice daily for 28 days) and the patient agreed to adhere to the treatment course. The left-knee swelling had gradually improved at 1 month of follow-up. Three days before the completion of doxycycline therapy, however, the left-knee effusion recurred and when examined by the rheumatologist the following week, the left knee had a 2+ effusion that persisted for an additional 9 days. The left-knee effusion subsequently resolved. The patient has had no further arthritis and remained well at 6 months of follow-up.

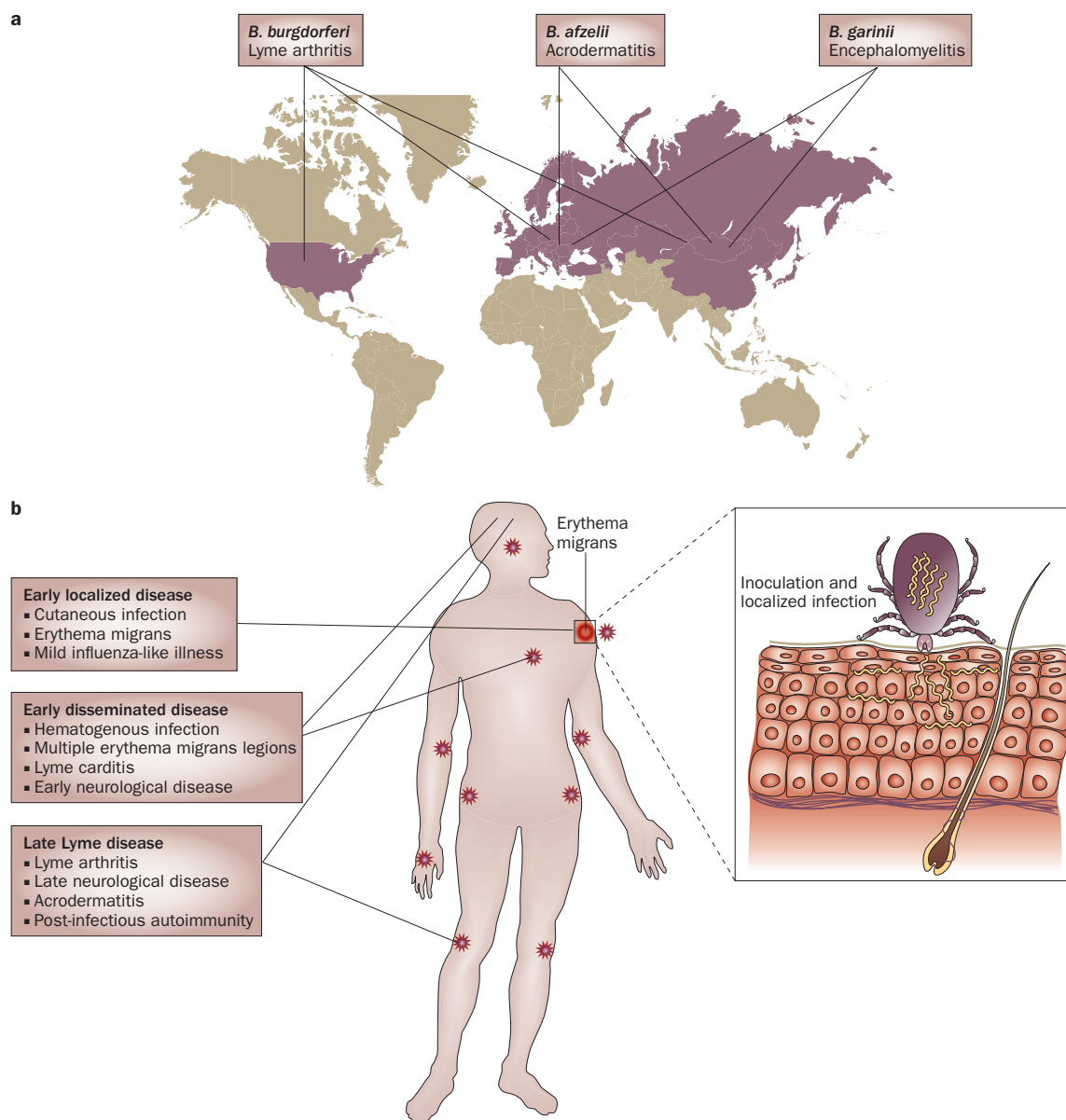
Diagnosis

Lyme disease was recognized in 1976 as an epidemic of oligoarthritis in children and adults in Lyme, Connecticut, USA.¹ In a prospective study, recurrent episodes of monoarthritis or oligoarthritis, particularly involving the knee, were reported in 60% of patients with Lyme disease.^{1,2} The causative organism in North America, *B. burgdorferi*, was isolated from the tick vector, *Ixodes scapularis*, in 1982.³ In Europe, Lyme disease is caused not only by *B. burgdorferi*, but also by other closely related borrelial species, including *B. afzelii*, infection with which is associated with acrodermatitis, and *B. garinii*, associated with encephalomyelitis (Figure 2a).⁴ Over the past 30 years, the geographic range of Lyme

disease has expanded and Lyme disease is now the most common vector-borne disease in both North America and Europe.⁵

Lyme disease has characteristic, well-recognized clinical features and is generally classified into early and late stages;⁶ early disease can be localized or disseminated (Figure 2b). Lyme disease typically begins with erythema migrans (EM) or other early-stage disease manifestations.⁷ Such early disease can be localized to the skin or can involve hematogenous dissemination to other sites, including the skin (multiple EM lesions), the heart (Lyme carditis) or the nervous system (early neurological disease).⁶ In general, Lyme disease is recognized early and with increasing accuracy in endemic areas, such as the coastal regions of Northeast USA. However, patients who are not treated for early disease (owing to a lack of early disease manifestations, a lack of detection or inadequate treatment) are at risk for late-stage disease, particularly Lyme arthritis in North America. Lyme arthritis is more common in North America than in Europe, because infection in North America is almost exclusively caused by *B. burgdorferi* and not other, less arthritogenic, borrelial species.^{2,4} Antibiotic treatment of early disease is usually curative;⁸ progression from early disease to late-stage arthritis, therefore, has become less common. In addition, the initiation of antibiotic therapy in patients who develop Lyme arthritis alters the natural history of the disease and shortens the number and duration of arthritic episodes.⁹

Although Lyme disease has become endemic in certain areas and the geographical range of Lyme disease has expanded,¹⁰ early recognition and treatment has resulted in a reduction in cases of early disseminated disease or progression to Lyme arthritis. Indeed, the natural history of untreated Lyme arthritis is rarely observed. This Case Study describes an individual who chose, over a period of years, to decline antibiotic therapy to treat her Lyme disease. The natural history of her disease is consistent with previous reports.^{1,2}



Lyme disease is a tick-borne spirochetal infection in which the earliest manifestations occur, as in this case, primarily during the late spring and early summer when nymphal *I. scapularis* ticks are active.^{7,11} This patient resided in Northeast USA, where Lyme disease is endemic, and reported that she was bitten by the tick vector *I. scapularis*. She developed EM, an expanding erythematous rash at the bite site, which is the most distinctive manifestation of early-stage Lyme disease and is observed in 80% of cases.^{7,11}

The patient experienced headache and a stiff neck 1 month after the tick bite, which might have been additional Lyme disease symptoms. Untreated early Lyme disease can be followed by a period of clinically asymptomatic infection, often lasting for several months;⁶ in this

patient, the asymptomatic period lasted for 10 months. However, at the onset of illness, hematogenous dissemination of *B. burgdorferi* from the skin to the joints allows for the development of late stage arthritis.^{12–14} On the basis of studies of the plasmid-rich genomic sequence of the causative organism, *B. burgdorferi*,¹⁵ it is thought that antigenic variation in multiple surface lipoproteins, including variable major protein-like sequence, expressed (VlsE), allows the organism to avoid recognition by the host immune system.¹⁶ During the progression to late-stage disease, an expanding range of immune responses develop against different antigenic determinants of *B. burgdorferi* that can be measured by Western blot analysis.^{17,18} Not surprisingly, when analyzed by this method, all serum samples from this patient had a markedly positive IgG

Box 1 | Treatment of Lyme arthritis***Lyme arthritis without neurologic disease**

Doxycycline 100 mg orally twice daily for 28 days
(pediatric dose: 1–2 mg/kg twice daily for 28 days)[†]

Amoxicillin 500 mg orally three times daily for 28 days
(pediatric dose: 25–50 mg/kg per day divided twice daily
for 28 days)

Persistent or recurrent Lyme arthritis[§]

Ceftriaxone 2 g per day intravenously for 14–28 days
(pediatric dose: 50–75 mg/kg per day intravenously for
14–28 days)^{||}

*In late-stage Lyme arthritis, the response to treatment can be delayed for several weeks or months. [†]Not recommended for children <8 years of age or for pregnant or lactating women; gastrointestinal toxicity and photosensitivity are common adverse effects. [§]Patients with mild persistent arthritis or recurrent arthritis can be treated with a second course of oral antibiotics. ^{||}Cefotaxime 2 g per 8 h intravenously is an acceptable alternative; the alternative dose in pediatric patients is 150–200 mg/kg per day in 3–4 divided doses (with a maximum of 6 g per day).

Western blot reaction. Indeed, the robustness of the immune response in Lyme arthritis suggests a possible anamnestic response to recurrent bacteremia.¹⁹

In the absence of treatment, the majority of North American patients with early Lyme disease will progress to Lyme arthritis, the most common late-stage manifestation.^{1,2} Late-stage neurological disease is very rare in North American patients, even in those who progress to Lyme arthritis. This patient illustrates the characteristic pattern of Lyme arthritis. She had migratory polyarthralgias–polyarthritis, occurring in brief episodes, followed by more persistent arthritis in one or more joints. This patient also had involvement of the knee with a considerable joint effusion.² In conjunction with these evolving clinical manifestations, a shift in the immune response of patients with Lyme disease to the expression of spirochete genes, including *bmpA* and *bmpB*, have been observed experimentally.²⁰

Once patients develop frank arthritis, they often experience recurrent arthritic flare-ups. The natural history of these episodes in any individual patient is somewhat unpredictable; however, the pattern of symptoms observed in this patient is typical—brief bouts of arthritis in one or several joints, followed by lengthy arthritic episodes in the knee.² The persistence of marked knee-swelling eventually caused the patient to consult a rheumatologist.

The patient, the homeopath and the rheumatologist all recognized Lyme disease owing to the highly characteristic clinical features. In addition, confirmatory laboratory testing supported the diagnosis. In early-stage Lyme disease, it is possible to culture *B. burgdorferi* from EM biopsy specimens,²¹ but such testing is usually unnecessary and is not routinely available. *B. burgdorferi* has also been cultured from blood samples in patients with early disease, but this method is not sensitive enough to be clinically reliable.^{12–14} Successful culture of *B. burgdorferi* from synovial fluid of patients with Lyme arthritis has rarely been reported,^{22,23} and is also not considered to be useful in clinical practice. Detection of *B. burgdorferi* in

synovial fluid by PCR is more sensitive than the aforementioned culturing techniques, but, to date, the utility of such testing has not been fully established for clinical decision-making.²⁴ The detection of humoral immune responses against *B. burgdorferi* by ELISA and Western blot, therefore, remain the primary diagnostic tests for Lyme disease.^{17–19} In early disease, seropositivity might not develop for several weeks, but as this case illustrates, by the time Lyme arthritis occurs, sera from all individuals will manifest a vigorous positive response to the ELISA and IgG Western blot assays.^{8,17,18}

Treatment

Several guidelines for the treatment of Lyme disease have been formulated, notably by Wormser *et al.*⁸ and an updated version was published by others in 2010.²⁵ Early localized Lyme disease is cured in almost all individuals with a short course of doxycycline or amoxicillin. Occasionally, patients with early disseminated Lyme disease (such as patients with Lyme meningitis) benefit from parenteral antibiotic therapy. Although the disease can resolve in some patients without antibiotic therapy, Lyme arthritis typically requires a longer duration of oral antibiotics or, occasionally, intravenous antibiotic therapy to be successful (Box 1).^{8,25}

During this patient's first presentation to the rheumatologist, the arthritis was observed to be resolving. Nevertheless, the rheumatologist recommended antibiotic therapy for two reasons: to hasten the resolution of the current bout of arthritis and, more importantly, to diminish the likelihood of subsequent episodes. The expectation of subsequent arthritic flare-ups was consistent with the previously studied natural history of untreated Lyme arthritis, in which recurrent episodes can occur for years.² After successful treatment of an incidence of Lyme arthritis with antibiotics, however, most patients are cured and have no further episodes of arthritis or other late manifestations of Lyme disease.^{8,9}

One of the reasons that the rheumatologist anticipated that antibiotic therapy would be successful in this patient, despite the delay in treatment, was that PCR studies demonstrated persistent *B. burgdorferi* synovial positivity in patients with untreated Lyme arthritis.²⁴ In a cohort of 88 patients, *B. burgdorferi* DNA was detected in the synovial fluid from 70 of 73 untreated patients (or those treated with a short course of antibiotics) compared with 7 of 19 patients who received parenteral antibiotics (or those treated with a long courses of oral antibiotics) (96% versus 37%, $P < 0.001$).²⁴ Furthermore, among a subgroup of 45 patients who had never received antibiotics, *B. burgdorferi* DNA was detected by PCR in 43 of 45 individuals (96%). Serial synovial samples were available for 12 of the untreated individuals in this subgroup. All 12 samples initially tested positive, and nine were subsequently positive when tested months or years later during subsequent episodes of arthritis. In the three patients for whom *B. burgdorferi* DNA was not detected in the last synovial fluid sample, their arthritis resolved within the following months.²⁴ This study suggests that the presence or absence of previous antibiotic treatment is more

predictive than the duration of untreated arthritis for the success of antibiotic therapy in Lyme arthritis.

Most individuals with Lyme arthritis respond to oral antibiotic therapy or, occasionally, parenteral antibiotic therapy (Box 1),²⁵ and can be clinically designated as antibiotic-responsive patients (defined as those who undergo successful antibiotic treatment in <3 months). A small percentage of patients, however, have a proliferative synovitis despite receiving 3 months of antibiotic therapy,^{9,26} and can be considered antibiotic-refractory (defined as patients who do not respond to >3 months of antibiotic therapy).⁹ It is not currently possible to prospectively identify the patients who will fail conventional antibiotic therapy. In some patients, Lyme arthritis is presumed to evolve from an infection to an immune-mediated illness for which both bacterial components^{16,20} and host factors^{9,27} determine the propensity and severity of the arthritis, and the responsiveness to treatment.

The optimum strategy to treat antibiotic-refractory patients with Lyme arthritis is unclear, but success has been reported with arthroscopic synovectomy of refractory arthritis in the knee,²⁸ and with short courses of disease-modifying antirheumatic drugs, including hydroxychloroquine.^{9,29} In some patients, physical therapy, NSAID medication and observation is appropriate since the natural history, even of antibiotic-refractory arthritis, is usually one of gradual resolution (Figure 3).² Antibiotic therapy for >3 months is unlikely to provide benefit in most patients⁸ and is not without risk.³⁰

Four years after the onset of Lyme disease, this patient accepted the recommendation of antibiotic treatment. She had previously started a 2-week course of doxycycline as prescribed by the homeopath, but, as there was no immediate resolution of arthritis, she discontinued this treatment. Several weeks later, she completed a 30-day course of doxycycline as prescribed by the rheumatologist, and, following a brief bout of arthritis in the left knee, stopped having recurrent arthritis. In patients with untreated Lyme arthritis, the natural history of the disease is characterized by recurrent flare-ups, lasting for up to 8 years with resolution observed in 10–20% of patients each year (Figure 3).² Antibiotic therapy terminated these recurrent arthritic episodes in this patient, and shortened the duration of illness.

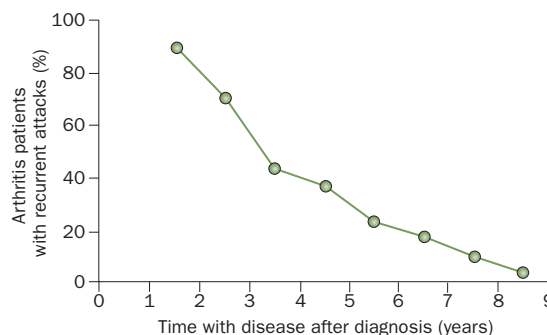


Figure 3 | The percentage of patients with Lyme arthritis who experience recurrent episodes decreases by year of disease. During the first year of illness, 90% of patients had bouts of arthritis, and the number of individuals who continued to have recurrences decreased by 10–20% each year. The mean number of months of active arthritis was 4 months and 5 months during the second and third years of the disease, respectively, and had decreased to ≤2 months by the fifth year. Reproduced with permission from the American College of Physicians © Steere, A. C. *et al. Ann. Intern. Med.* **107**, 725–731 (1987).

Conclusion

When Lyme disease was recognized >30 years ago, the spirochetal etiology was unknown.¹ Following the recognition that Lyme disease is caused by *B. burgdorferi* infection in 1983,^{12,13} almost all patients with recognized EM or Lyme arthritis are promptly treated with antibiotic therapy. Rheumatologists are, therefore, rarely visited by patients who illustrate the natural history of untreated Lyme arthritis. Nevertheless, patients who are not treated with antibiotic therapy are known to have recurrent episodes of oligoarthritis, often affecting the knee.³ Indeed, this Case Study demonstrates that Lyme arthritis, if untreated, continues to occur in a well-characterized pattern that can last for years. Furthermore, the arthritis in this patient is thought to have resulted from *B. burgdorferi* infection (in the absence of previous antibiotic therapy) rather than a postinfectious inflammatory process, and her condition was cured with a relatively short course of antibiotic treatment. The clinical identification of this increasingly uncommon long-term form of Lyme arthritis is important and appropriate management, even at this late-stage of disease, can result in gratifying treatment outcomes.

- Steere, A. C. *et al.* Lyme arthritis: an epidemic of oligoarticular arthritis in children and adults in three Connecticut communities. *Arthritis Rheum.* **20**, 7–17 (1977).
- Steere, A. C., Schoen, R. T. & Taylor, E. The clinical evolution of Lyme arthritis. *Ann. Intern. Med.* **107**, 725–731 (1987).
- Burgdorfer, W. *et al.* Lyme disease—a tick-borne spirochetosis? *Science* **216**, 1317–1319 (1982).
- van Dam, A. P. *et al.* Different genospecies of *Borrelia burgdorferi* are associated with distinct clinical manifestations of Lyme borreliosis. *Clin. Infect. Dis.* **17**, 708–717 (1993).
- Dennis, D. T. & Hayes, E. B. in *Lyme Borreliosis: Biology, Epidemiology and Control* (eds Gray, J. S., Kahl, O., Lane, R. S. & Stanek, G.) 251–280 (CABI, Oxfordshire, 2002).
- Steere, A. C. Lyme disease. *N. Engl. J. Med.* **321**, 586–596 (1989).
- Steere, A. C. *et al.* The early clinical manifestations of Lyme disease. *Ann. Intern. Med.* **99**, 76–82 (1983).
- Wormser, G. P. *et al.* The clinical assessment, treatment, and prevention of Lyme disease, human granulocytic anaplasmosis, and babesiosis: clinical practice guidelines by the Infectious Disease Society of America. *Clin. Infect. Dis.* **43**, 1089–1134 (2006).
- Steere, A. C. & Angelis, S. M. Therapy for Lyme arthritis: strategies for the treatment of antibiotic-refractory arthritis. *Arthritis Rheum.* **54**, 3079–3086 (2006).
- Bacon, R. M., Kugeler, K. J. & Mead, P. S. Surveillance for Lyme disease—United States, 1992–2006. *MMWR Surveill. Summ.* **57**, 1–9 (2008).
- Smith, R. P. *et al.* Clinical characteristics and treatment outcomes of early Lyme disease in patients with microbiologically confirmed erythema migrans. *Ann. Intern. Med.* **136**, 421–428 (2002).
- Steere, A. C. *et al.* The spirochetal etiology of Lyme disease. *N. Engl. J. Med.* **308**, 733–740 (1983).
- Benach, J. L. *et al.* Spirochetes isolated from the blood of two patients with Lyme disease. *N. Engl. J. Med.* **308**, 740–742 (1983).
- Wormser, G. P. *et al.* Brief communication: hematogenous dissemination in early Lyme disease. *Ann. Intern. Med.* **142**, 751–755 (2005).

15. Fraser, C. M. *et al.* Genomic sequence of a Lyme disease spirochaete, *Borrelia burgdorferi*. *Nature* **390**, 580–586 (1997).
16. Liang, F. T. *et al.* An immunodominant conserved region within the variable domain of VlsE, the variable surface antigen of *Borrelia burgdorferi*. *J. Immunol.* **163**, 5566–5573 (1999).
17. Craft, J. E., Grodzicki, R. L. & Steere, A. C. The antibody response in Lyme disease: evaluation of diagnostic tests. *J. Infect. Dis.* **149**, 789–795 (1984).
18. Dressler, F., Whalen, J. A., Reinhardt, B. N. & Steere, A. C. Western blotting in the serodiagnosis of Lyme disease. *J. Infect. Dis.* **167**, 392–400 (1993).
19. Aguero-Rosenfeld, M. E. Lyme disease: laboratory issues. *Infect. Dis. Clin. North Am.* **22**, 301–313 (2008).
20. Pal, U. *et al.* *Borrelia burgdorferi* basic membrane proteins A and B participate in the genesis of Lyme arthritis. *J. Exp. Med.* **205**, 133–141 (2008).
21. Berger, B. W., Kaplan, M. H., Rothenberg, I. R. & Barbour, A. G. Isolation and characterization of the Lyme disease spirochete from the skin of patients with erythema chronicum migrans. *J. Am. Acad. Dermatol.* **13**, 444–449 (1985).
22. Syndman, D. R., Schenkein, D.P., Berardi, V. P., Lastavica, C. C. & Pariser, K. M. *Borrelia burgdorferi* in joint fluid in chronic Lyme arthritis. *Ann. Intern. Med.* **104**, 798–800 (1986).
23. Schmidli, J., Hunziker, T., Moesli, P. & Schaad, U. B. Cultivation of *Borrelia burgdorferi* from joint fluid three months after treatment of facial palsy due to Lyme borreliosis. *J. Infect. Dis.* **158**, 905–906 (1988).
24. Nocton, J. J. *et al.* Detection of *Borrelia burgdorferi* DNA by polymerase chain reaction in synovial fluid in Lyme arthritis. *N. Engl. J. Med.* **330**, 229–234 (1994).
25. Treatment of Lyme disease. *Medical Letter on Drugs and Therapeutics* **52**, 53–54 (2010).
26. Steere, A. C., Duray, P. H. & Butcher, E. C. Spirochetal antigens and lymphoid cell surface markers in Lyme synovitis. Comparison with rheumatoid synovium and tonsillar lymphoid tissue. *Arthritis Rheum.* **31**, 487–495 (1988).
27. Iliopoulou, B. P. & Huber, B. T. Infectious arthritis and immune dysregulation: lessons from Lyme disease. *Curr. Opin. Rheumatol.* **22**, 451–455 (2010).
28. Schoen, R. T., Aversa, J. M., Rahn, D. E. & Steere, A. C. Treatment of refractory chronic Lyme arthritis with arthroscopic synovectomy. *Arthritis Rheum.* **34**, 1056–1060 (1991).
29. Coblyn, J. S. & Taylor, P. Treatment of chronic Lyme arthritis with hydroxychloroquine. *Arthritis Rheum.* **24**, 1567–1569 (1981).
30. Holzbauer, S. M., Kemperman, M. M. & Lynfield, R. Death due to community-associated *Clostridium difficile* in a woman receiving prolonged antibiotic therapy for suspected Lyme disease. *Clin. Infect. Dis.* **51**, 369–370 (2010).

Acknowledgments

Written consent for publication was obtained from the patient.